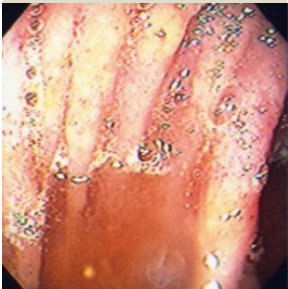

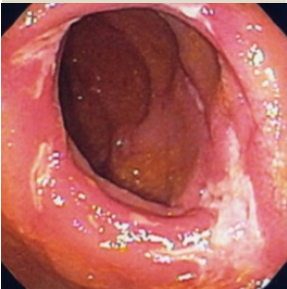
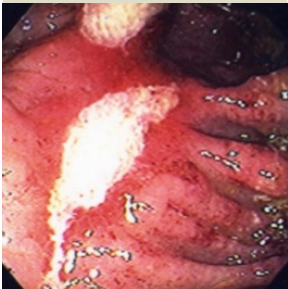
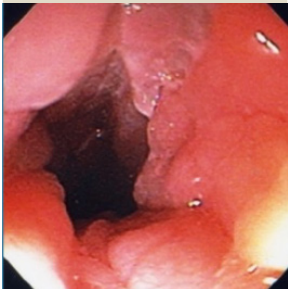


## The Neo-Terminal Ileum: The Rutgeerts Score

i0	i1	i2	i3	i4
				
No lesions	<5 aphthous lesions	>5 aphthous lesions with normal mucosa between the lesions, or skip areas of larger lesions, or lesions confined to the ileocolonic anastomotic lining (<1 cm)	Diffuse aphthous ileitis with diffusely inflamed mucosa	Diffuse ileal inflammation with larger ulcers, nodules, or narrowing

Recurrence of inflammation in the neoterminal ileum is graded for severity as follows: no or mild recurrence, (i.e., i0 or i1) and severe recurrence, (i.e., i2-i4 severe diffuse aphthous or ulcerative ileitis). Most studies adjust therapy for findings >i1.